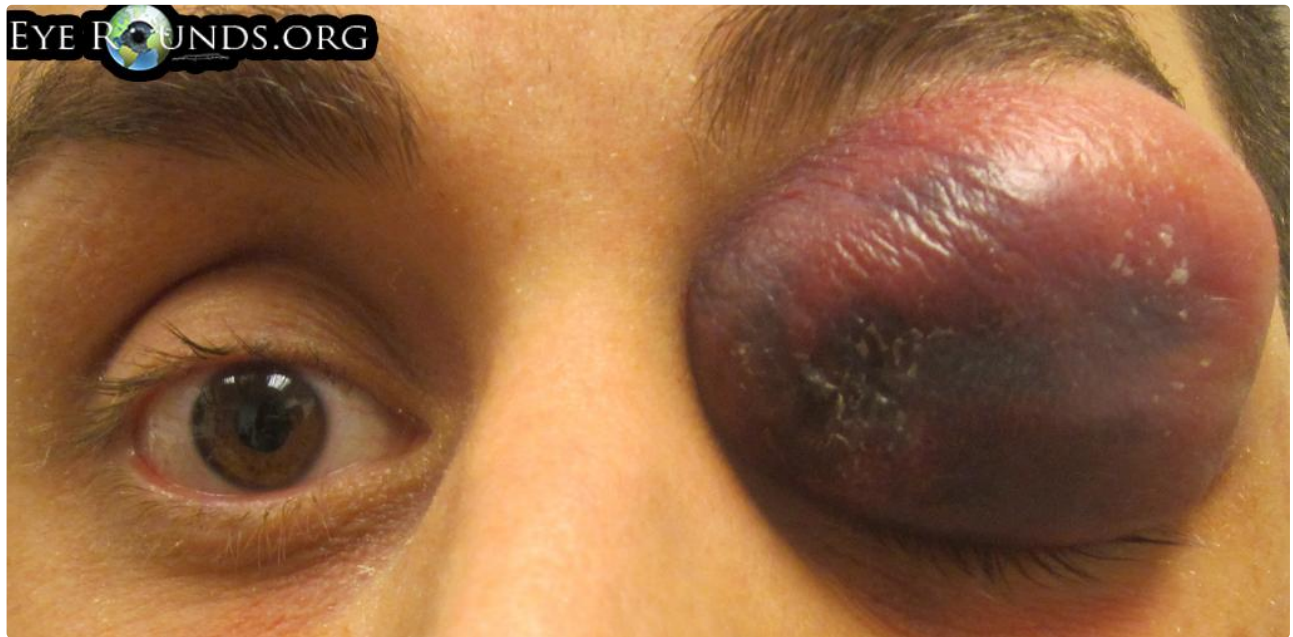

Methicillin-resistant Staphylococcus aureus (MRSA) preseptal cellulitis

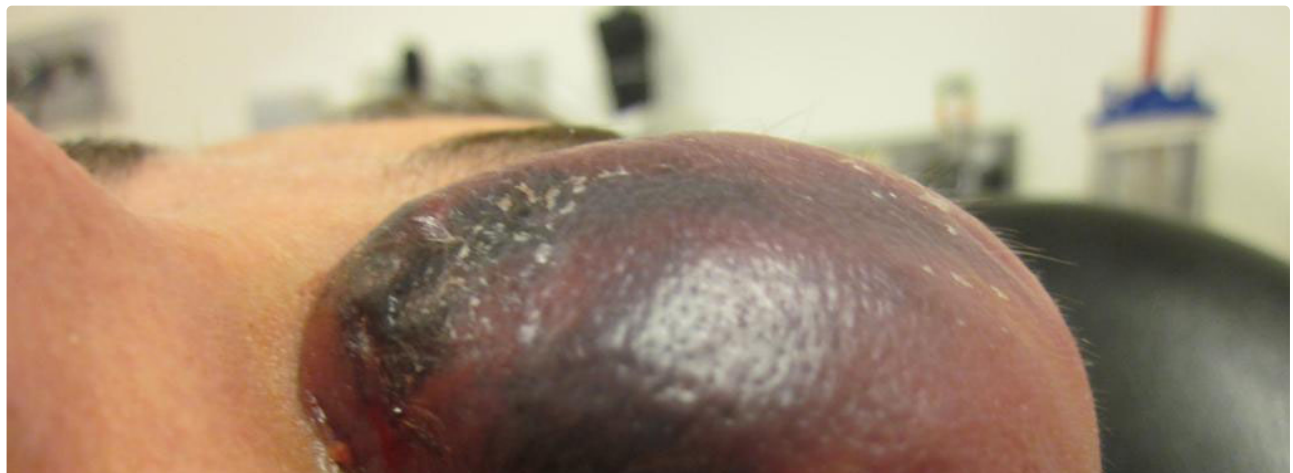Category(ies): Oculoplastics

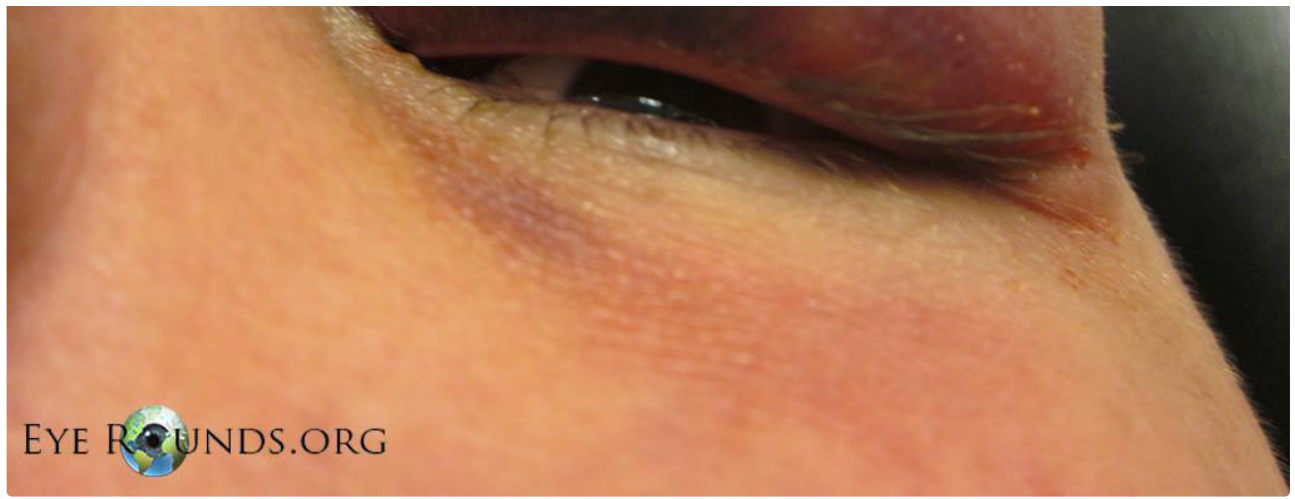
Contributor: [Elizabeth Gauger, MD](#)

31-year-old male who works in a nursing home, was transferred from an outside hospital for rapidly progressive lid swelling and overlying hemorrhage over the course of 4 days. This preseptal cellulitis was unresponsive to oral antibiotics. In our clinic, he underwent incision and drainage (I&D), and the cultures returned positive for methicillin-resistant Staphylococcus aureus (MRSA). He is at risk for being a carrier of MRSA given his employment in a nursing home. His clinical course improved rapidly with I&D of his lesion, frequent hot compresses, and parenteral vancomycin therapy. Several months later, his appearance was back to his baseline, with no long-term sequelae.



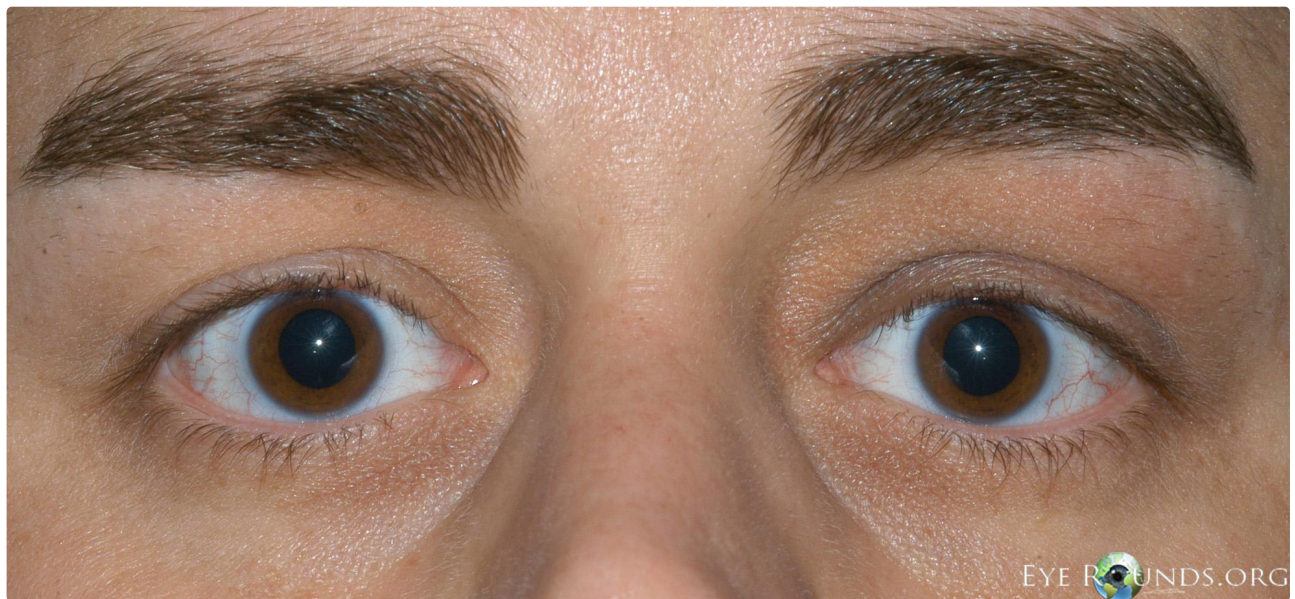[Enlarge](#) [Download](#)





EYE ROUNDS.ORG

[Enlarge](#) [Download](#)



EYE ROUNDS.ORG

Photo: 6 weeks after treatment.

[Enlarge](#) [Download](#)

Image Permissions:



Ophthalmic Atlas Images by EyeRounds.org, The University of Iowa are licensed under a [Creative Commons Attribution-NonCommercial-NoDerivs 3.0 Unported License](https://creativecommons.org/licenses/by-nc-nd/3.0/).



Related Articles

Address

University of Iowa
Roy J. and Lucille A. Carver College
of Medicine
Department of Ophthalmology and
Visual Sciences
200 Hawkins Drive
Iowa City, IA 52242

[Support Us](#)

Legal

Copyright © 2019 The University of
Iowa. All Rights Reserved
[Report an issue with this page](#)
[Web Privacy Policy](#) |
[Nondiscrimination Statement](#)

Related Links

[Cataract Surgery for Greenhorns](#)
[EyeTransillumination](#)
[Gonioscopy.org](#)
[Iowa Glaucoma Curriculum](#)
[Iowa Wet Lab](#)
[Patient Information](#)
[Stone Rounds](#)
[The Best Hits Bookshelf](#)

EyeRounds Social Media

Follow



[Receive notification of new cases,
sign up here](#)
[Contact Us](#)
[Submit a Suggestion](#)